

รายงานผู้ป่วย (Case report)

Hematoma after Intramuscular Diclofenac Injection Mimic Sciatica Pain in Lumbar Radiculopathy: A Case Report

Yutthana Khanasuk (M.D.), Nattawut Sastravaha (M.D.), Surapon Atiprayoon (M.D.) and Worasun Taweewuthisub (M.D.)

Department of Orthopaedics, Queen SavangVadhana Memorial Hospital

Abstract

Introduction Nerve injection injuries are common and the most common injured nerve is sciatic nerve. This report was demonstrated a patient who has problem after diclofenac intramuscular injection.

Report A 50-year-old male with lumbar radiculopathy. He was treated with diclofenac injection. Three weeks later, he came back again with severe sciatica pain. He was diagnosed with a mass irritated sciatic nerve. He underwent an immediate exploration and open debridement. The intraoperative finding was 100 ml of blood located beneath of gluteal medius area. No pus or infected material were observed. His sciatica pain was disappeared after surgery. The specimens culture were negative after 3 days of incubation.

Discussion Intramuscular diclofenac injection frequently produces pain after injection. There are several reports the sciatic nerve injection injury (SNII) but they focused only direct trauma and drug associated with SNII. This is a first report of a hematoma mimic sciatica besides the direct nerve trauma or agent related with SNII.

Conclusion Pain after diclofenac injection may cause by direct sciatic injury or hematoma formation from small vessel injury. The location of injection is important and it will be safer with longer compression.

Keywords Sciatica, Sciatic nerve injection injury, Nerve injury, Diclofenac injection

Corresponding author Yutthana Khanasuk. Department of Orthopaedics, Queen SavangVadhana Memorial Hospital, Sriracha, Chonburi, Thailand
Email: laobungchai@gmail.com

ก้อนเลือดที่เกิดขึ้นภายหลังจากการฉีดยาไดโคลฟีแนกเข้ากล้ามเนื้อสามารถเลียนแบบอาการปวดร้าวลงขาแบบเดียวกับอาการกระดูกหลังเสื่อม : รายงานผู้ป่วย

ยุทธนา คณาสุข (พ.บ.), ญัฐวุธ ศาสตราวหา (พ.บ.), สุรพล อธิประยูร (พ.บ.) และ วรสันต์ ทวีวุฒิทรัพย์ (พ.บ.)

ฝ่ายศัลยกรรมกระดูกและข้อ โรงพยาบาลสมเด็จพระบรมราชเทวี ณ ศรีราชา

บทคัดย่อ

บทนำ การบาดเจ็บของเส้นประสาทจากการฉีดยา เป็นภาวะที่พบได้บ่อย โดยเฉพาะเส้นประสาทไซอะติก รายงานฉบับนี้ นำเสนอผู้ป่วยที่เส้นประสาทไซอะติก ได้รับบาดเจ็บจากการฉีดยาไดโคลฟีแนกเข้ากล้ามเนื้อ

วิธีการและผลการศึกษา ผู้ป่วยชายอายุ 50 ปี มาพบแพทย์ด้วยอาการปวดหลังร้าวลงขา เขาได้รับการรักษาด้วยการฉีดยาไดโคลฟีแนกเข้ากล้ามเนื้อที่บริเวณสะโพก 3 สัปดาห์ต่อมา เขามีอาการปวดแบบเดิมที่รุนแรงมาก เขามาพบแพทย์อีกครั้งและได้รับการวินิจฉัยว่า มีก้อนไปกดทับเส้นประสาทไซอะติก และได้รับการผ่าตัดอย่างเร่งด่วน ซึ่งพบว่า ก้อนที่มาก้อนนั้นเป็นก้อนเลือดขนาด 100 มิลลิลิตร อยู่ใต้ต่อชั้นกล้ามเนื้อบริเวณสะโพก โดยที่ไม่ใช่ลักษณะของฝีหนอง และผลการเพาะเชื้อภายหลังยืนยันได้ผลลบ

อภิปราย ปัญหาความเจ็บปวดหลังการฉีดยาไดโคลฟีแนกเข้ากล้ามเนื้อ เป็นสิ่งที่พบได้บ่อยในทางคลินิก ซึ่งมีรายงานทางการแพทย์มากมาย รายงานฉบับนี้ เป็นรายงานฉบับแรกๆ ที่แสดงว่า ก้อนเลือดที่เกิดขึ้นหลังจากการฉีดยาเข้ากล้ามเนื้อ ซึ่งอาจเกิดภายหลังจากการฉีดยา ทำให้เกิดการกดทับของเส้นประสาท เลียนแบบการบาดเจ็บที่พบได้บ่อย คือการบาดเจ็บจากเข็มฉีดยาหรือตัวยาโดยตรง

สรุป ความเจ็บปวดหลังจากการฉีดยา ไดโคลฟีแนกเข้ากล้ามเนื้อ สามารถเกิดได้จากการบาดเจ็บโดยตรง หรือจากการที่มีก้อนเลือดมากกดทับ ซึ่งก้อนเลือดนี้มาจากการบาดเจ็บของหลอดเลือดขนาดเล็กภายหลังจากการฉีดยา ซึ่งสามารถป้องกันได้ด้วยการเลือกตำแหน่งฉีดยาให้เหมาะสม รวมถึงการกดบริเวณที่ฉีดยาให้นานพอ

คำสำคัญ อาการปวดร้าวลงขา การบาดเจ็บของเส้นประสาทไซอะติก การฉีดยาไดโคลฟีแนก

ผู้นิพนธ์ที่รับผิดชอบ ยุทธนา คณาสุข

โรงพยาบาลสมเด็จพระบรมราชเทวี ณ ศรีราชา อำเภอศรีราชา จังหวัดชลบุรี ประเทศไทย

Email: laobungchai@gmail.com

Introduction

Sciatica pain is a common symptom caused by spinal stenosis or nerve irritation, known as radiculopathy. The treatment begins with conservative treatment including medication, physiotherapy and alternative medicine such as acupuncture. Spinal nerve root block is a less invasive procedure that improve radiculopathy symptoms. Patients who have failure conservative treatment are considering for surgery.

For conservative treatment, Non Steriodal Anti-inflammatory Drugs (NSAIDs) play a major role in pain control. General side effects of NSAIDs including gastrointestinal disturbance, cardiovascular toxicity, and renal complications. Injectable form of NSAIDs is a common used medication to cope with acute pain. Example of parenteral NSAIDs are diclofenac, ketorolac and parecoxib.

Ketorolac and parecoxib are able to give to the patient by both intravenous and intramuscular route. But diclofenac commonly administrates by intramuscularly. Because of one ampule of diclofenac contains in a 3 mL (75 mg) and its structure is crystal, a common adverse event after intramuscular shot is pain at injection site. Diclofenac can also injected via intravenously but the preparation before injection must very strict including well alkalize until the crystal dissolve to the solution, slow administration and must immediately injected after preparation. Otherwise diclofenac may caused severe venous irritation or thromboembolism.

Objective

This report was demonstrated a patient who has problem after diclofenac intramuscular injection.

Report

A 50-year-old male who suffered from lumbar radiculopathy, came to hospital because of back and sciatica pain. He was diagnosed as lumbar stenosis. He was treated conservatively by NSAIDs, muscle relaxant and gabapentinoids. Furthermore he was given an injection of diclofenac. His weight was 56 kilograms and he has 169-centimeter height.

He was followed up with slightly improved of sciatica and back pain. Three weeks later, he came back due to severe sciatica pain for 2 days. He denied of trauma or other injury. He did not have any fever. The physical examination reveal straight leg raising test positive at 45 degree. Motors power were grade 5 all. The deep tendon reflexes were normal.

The basic investigations found normal range of complete blood count, renal function test, liver function test, electrolytes and coagulogram. His lumbosacral imaging showed mild grade of spondylosis. The doctor incharge decided to send him Magnetic Resonance Imaging (MRI) because of acute severe symptom. The differential diagnosis were acute lumbar disc herniation, other nerve root canal irritation, nerve injury from intramuscular injection.

The MRI reveals an iso-signal intensity lesion, 5x5x8.8 centrimeters in diameter, at right gluteus medius muscle with irregular rim enhancement of the lesion. Abnormal enhancement is also seen at lateral aspect of right piriformis muscle and sciatic nerve (see in figure 1 to 3). The radiologist concluded that the mass could be infectious process of right gluteus medius, piriformis and sciatic nerve.

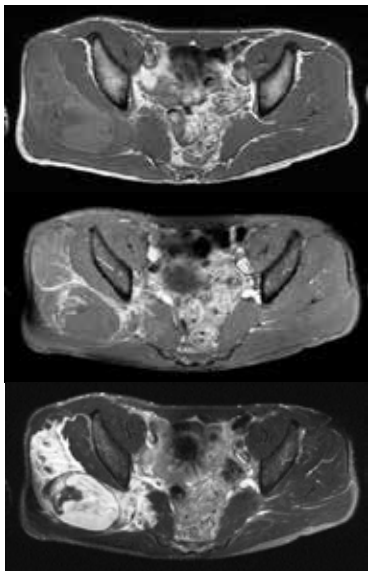


Figure 1 demonstrated MRI axial T1W, T1W with Gadolinium (Gd) and T2W fat suppression view respectively.

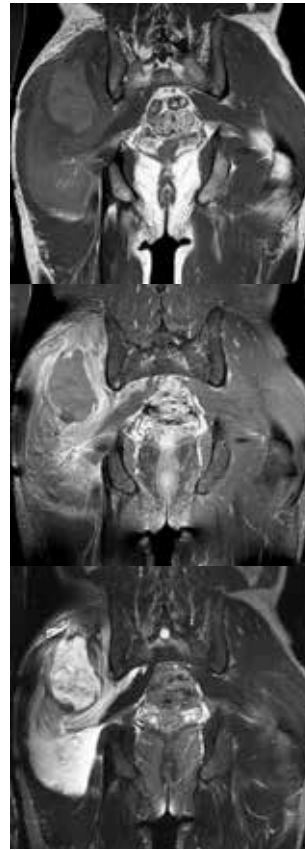


Figure 2 demonstrated MRI coronal T1W, T1W with Gd and T2W fat suppression view respectively.

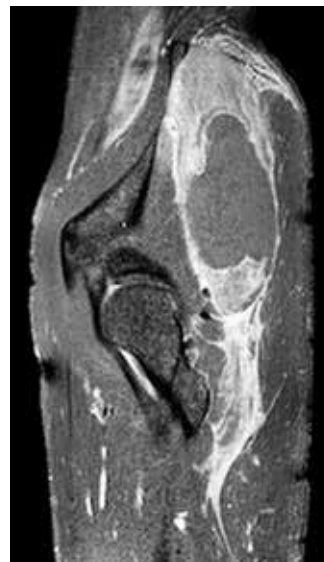

Figure 3 demonstrate a sagittal T1W with Gd.

The patient was scheduled for urgent open debridement and hip arthrotomy. The intraoperative finding was only 100 ml of hematoma located beneath of gluteal medius area. No pus or infected material were observed. After remove clot and irrigation with normal saline and antiseptic, the wound was closed with vacuum drainage. The clinical symptoms of sciatica pain was disappeared after surgery. The specimens culture were negative after 3 days incubation.

Discussion

Nerve injection injuries are common but they are under-reported 1,2. The most common injury nerve is sciatic nerve. The overall incidence of sciatic nerve injection injury (SNII) is unknown because of under record. Risk factors of SNII are low economic status, inadequate training, small gluteal mass, young age, thin body built 1,3,4.

Three main mechanisms of injury^{5,6} are direct needle trauma, drug induced ischemia and drug associated with nerve injury. Direct nerve trauma caused by the technique of injection, position of the needle, the length of the needle and the practitioners. Nerve ischemia may induced fibrosis and caused neural constriction and also increased intraneural pressure. Some medications are reported that associated with SNII such as ropivacaine, lidocaine, diclofenac, tramadol, meperidine, penicillin, gentamicin, cefuroxime⁷.

The recommend location of injected site is dorsogluteal region (upper and outer

quadrant of the buttock)⁸⁻¹⁰. Some authors suggested ventrogluteal which located more lateral, more superior than dorsogluteal region. The beneficial points including the subcutaneous is thinner, hydrophilic chemicals are well absorbed and the muscle is thicker.

Nearly 90% of SNII presentation with immediate onset of symptoms whereas 10% of patients have delayed onset ranging from minutes to hours after injection¹¹. The symptoms are presented with pain, paresthesia or weakness. SNII is diagnosed by clinical examination, MRI and electrodiagnosis study which including nerve conduction velocity and electromyography^{12,13}.

Diclofenac is a common NSAIDs medication which relieve acute pain via inhibition of prostaglandin synthesis by cyclooxygenase blockage. It is a cheap, good pain relieve, easy to find medicine and has low rate to allergy. But the parenteral form of diclofenac commonly injected intramuscularly, which commonly produce pain after injection. Furthermore, intramuscular may resulted in SNII.

This case report demonstrate the other problem besides direct nerve trauma or agent related with SNII, a hematoma. . The MRI that demonstrated a mass that irritated sciatic nerve and cause severe radiculopathy. Intramuscular injection may injured the vessels that cause a hematoma formation. By nature, small hematoma may absorb itself follow by time. This case calls for concern about ongoing bleeding after injection and caused

a serious problem. Even though general recommendation after intramuscular injection is massage the area of injection to stimulate the circulation and enhance absorption, a short period of compression before massage will ensure that the bleeding is stop properly.

For SNII prevention, intramuscular injection should be avoid especially in patient who have high risk to injury as mentioned before. In terms of prevention a hematoma formation, longer pressure is recommended. The practitioner will make sure that the bleeding was stop properly especially in patient who are risk to have a hematoma such as bleeding tendency, thin gluteal mass, anticoagulant or antiplatelet user.

Conclusion

Pain after diclofenac injection can be from iatrogenic practice such as direct sciatic injury or hematoma formation from small vessel injury. The landmark for gluteal intramuscular injection was important and it will be safer with longer compression.

References

1. Mishra P, Stringer MD. Sciatic nerve injury from intramuscular injection: A persistent and global problem. *Int Clin J Pract* 2010; 64: 1573-9.
2. Ipp MM, Gold R, Goldbach M, Maresky DC, Saunders N, Greenberg S, et al. Adverse reactions to diphtheria, tetanus, pertussis-polio vaccination at 18 months of age: Affect of injection site and needle length. *Pediatrics* 1989; 83: 679-82.
3. Ramthahai J, Ramlakhan S. Sciatic nerve injury following intramuscular injection: a case report and review of the literature. *J Neurosci Nurs* 2006; 38: 238-40.
4. Jung Kim H, Hyun Park S. Sciatic nerve injection injury. *J Int Med Res* 2014; 42: 887-97.
5. Ong MJ, Lim GH, Kei PL. Clinics in diagnostic imaging (140). Iatrogenic sciatic nerve injury secondary to intramuscular injection. *Singapore Med J* 2012; 53: 551-4.
6. Yeremeyeva E, Kline DG, Kim DH. Iatrogenic sciatic nerve injuries at buttock and thigh levels: The Louisiana State University experience review. *Neurosurgery* 2009; 65(suppl 4): A63-6.
7. Mackinnon SE, Hudson AR, Gentili F, Kline DG, Hunter D. Peripheral nerve injection injury with steroid agents. *Plast Reconstr Surg* 1982; 69: 482-90.
8. Currin SS, Mirjalili SA, Meikle G, Stringer MD. Revisiting the surface anatomy of the sciatic nerve in the gluteal region. *Clin Anat* 2015; 28: 144-9.
9. Cook IF, Murtagh J. Ventrogluteal area - A suitable site for intramuscular vaccination of infants and toddlers. *Vaccine* 2006; 24: 240-8.

10. Rodger MA, King L. Drawing up and administering intramuscular injections: A review of the literature. *J Adv Nurs* 2000; 31: 574-82.
11. Maqbool W, Sheikh S, Ahmed A. Clinical, electrophysiological, and prognostic study of postinjection sciatic nerve injury: an avoidable cause of loss of limb in the peripheral medical service. *Ann Indian Acad Neurol* 2009; 12: 116-9.
12. Bhattacharjee S, Bannerjee TK, Bhattacharjee AK, Ghosh I. Intramuscular injection: an uncommon cause of ipsilateral foot drop. *Br J Hosp Med (Lond)* 2013; 74:112-3.
13. Kline DG, Kim D, Midha R, Harsh C, Tiel R. Management and results of sciatic nerve injuries: A 24-year experience. *J Neurosurg* 1978; 89:13-23.
14. Gentili F, Hudson AR, Hunter D. Clinical and experimental aspects of injection injuries of peripheral nerves. *Can J Neurol Sci* 1980; 7: 143-51.